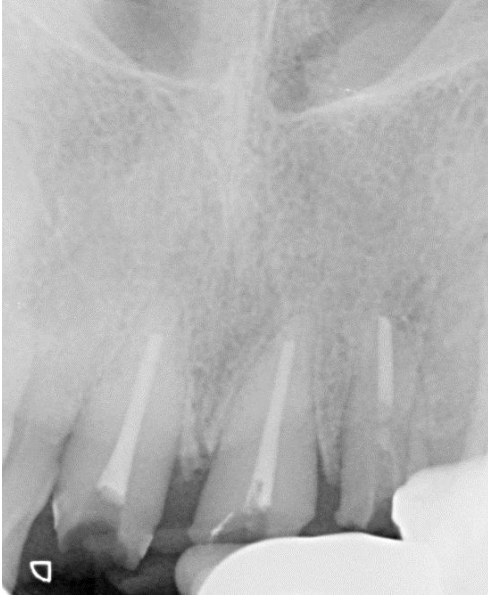
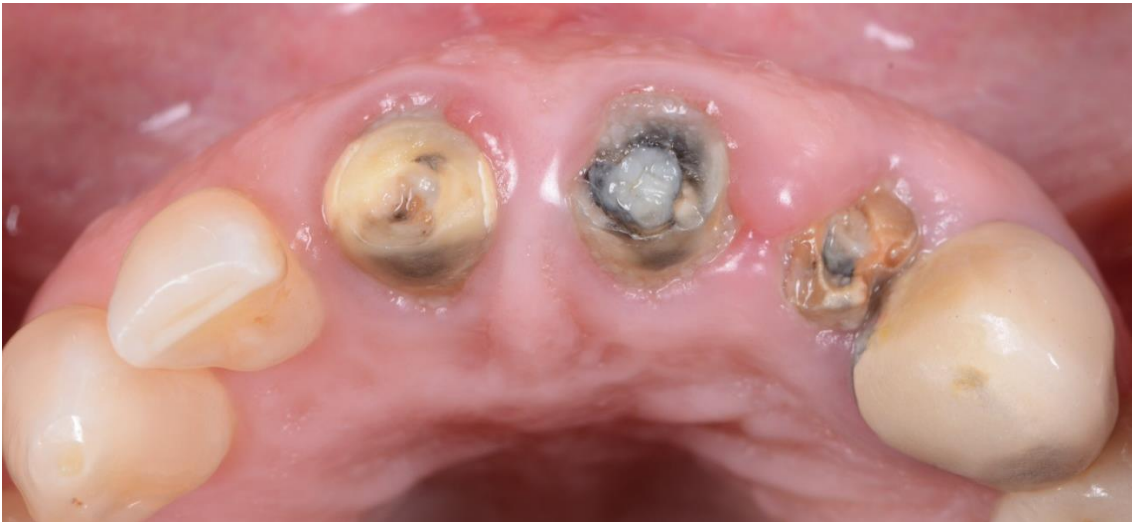
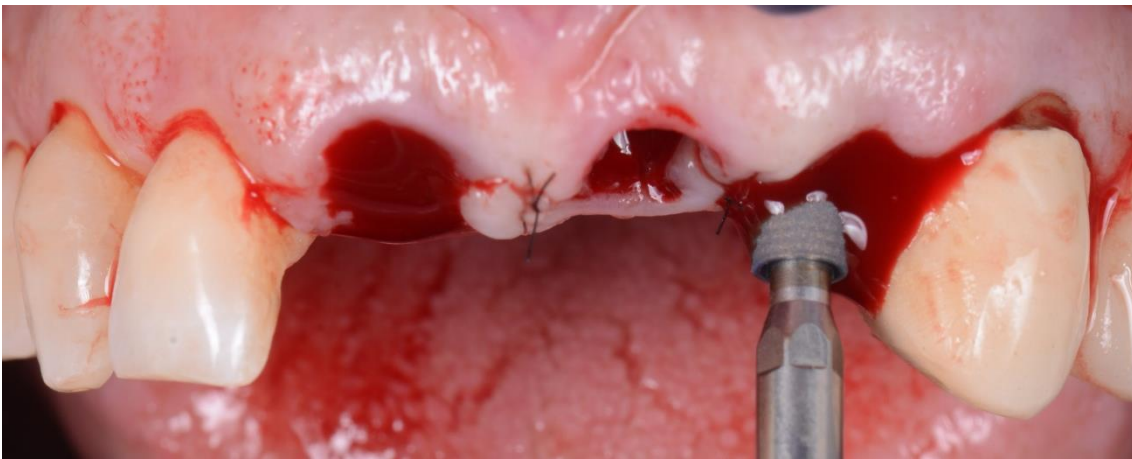
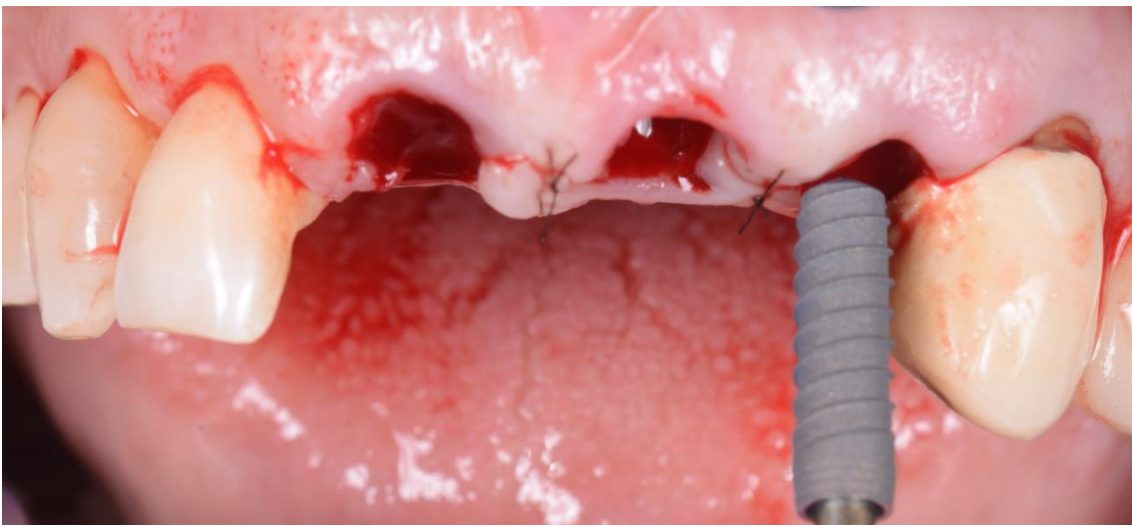
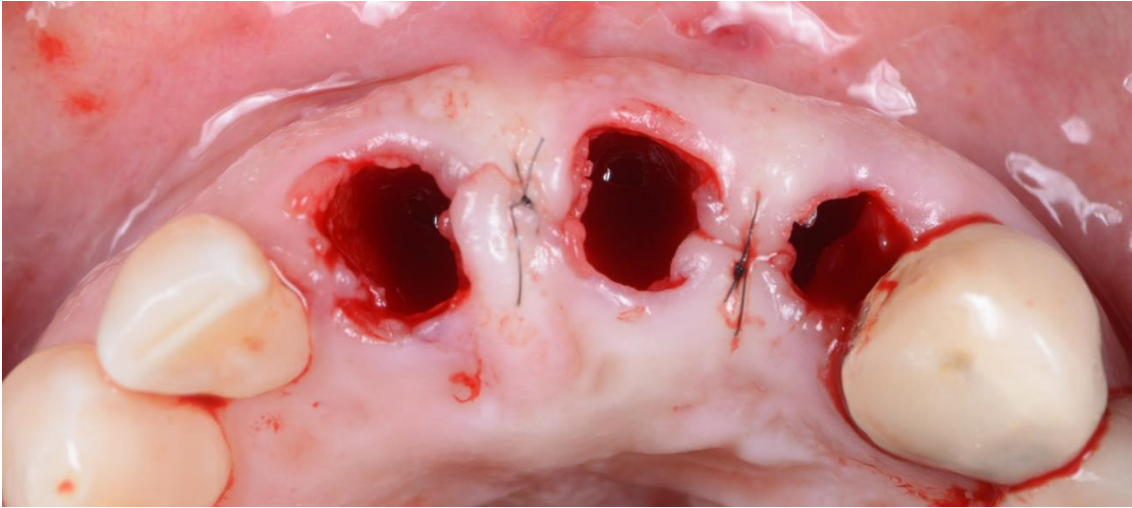
CASO CLÍNICO 1

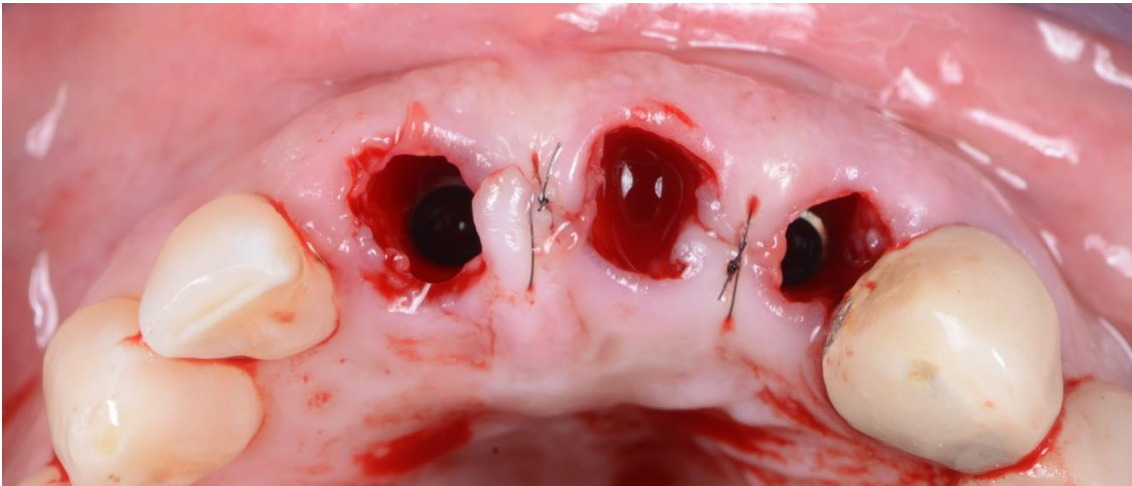
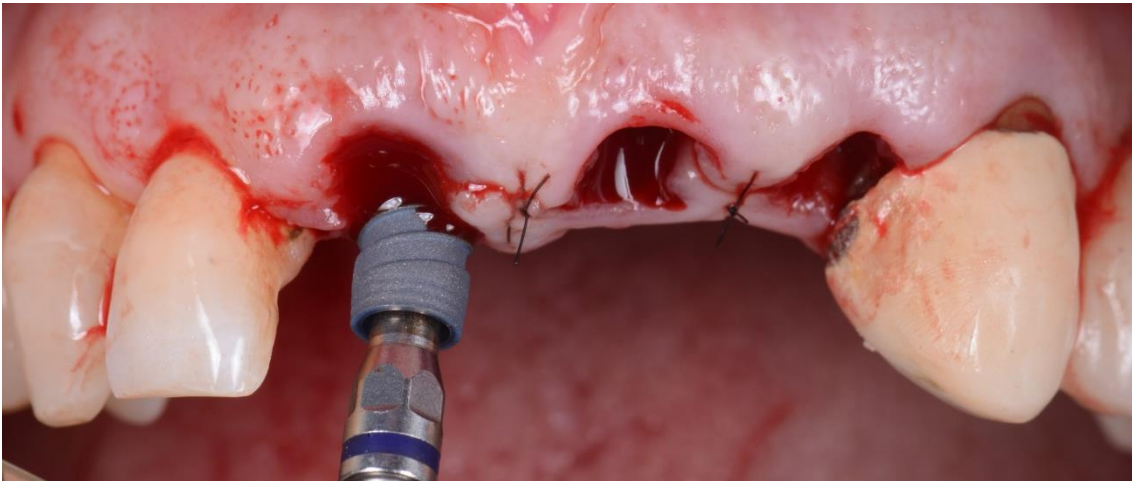
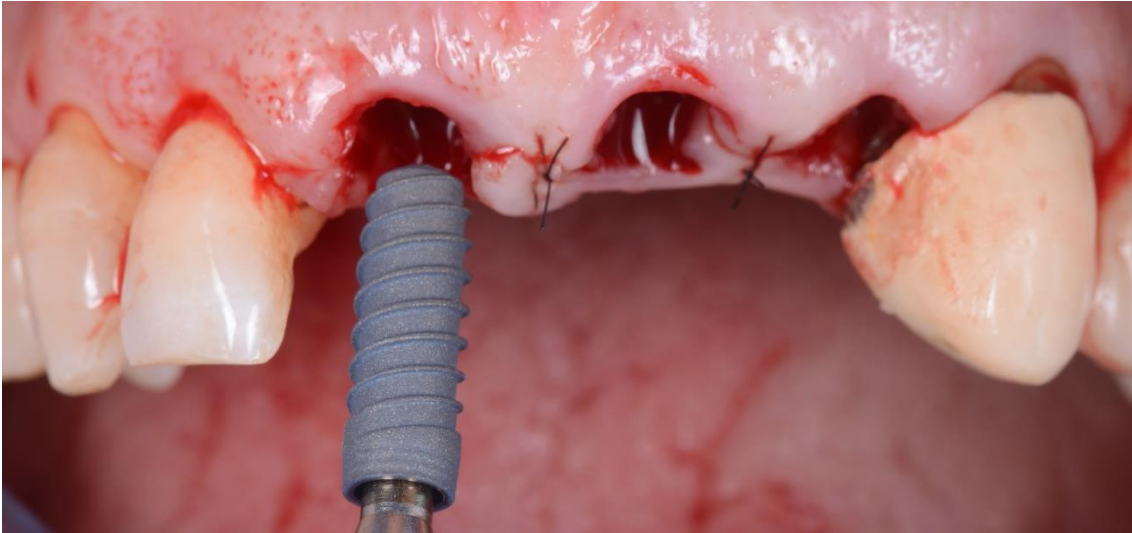
PERIAPICAL PREVIA

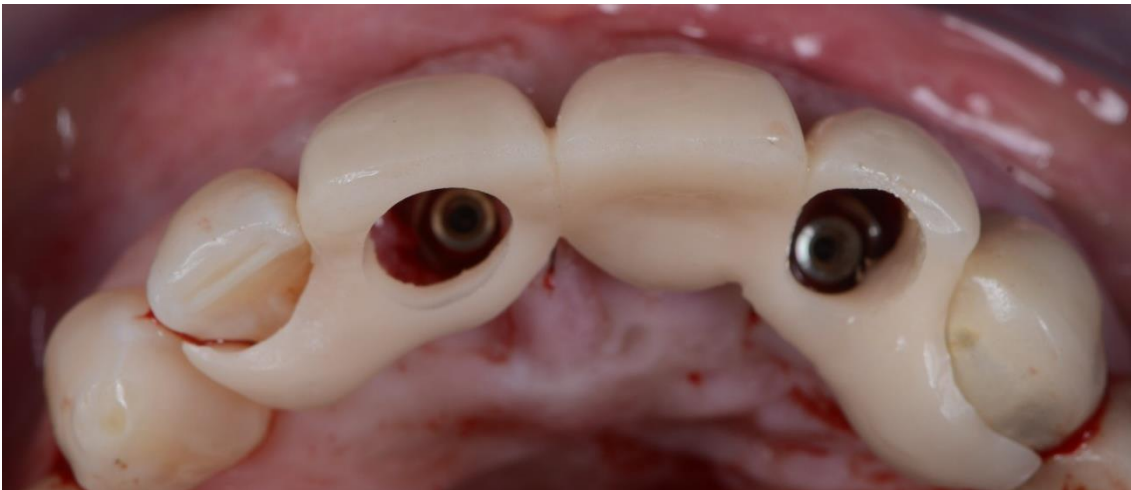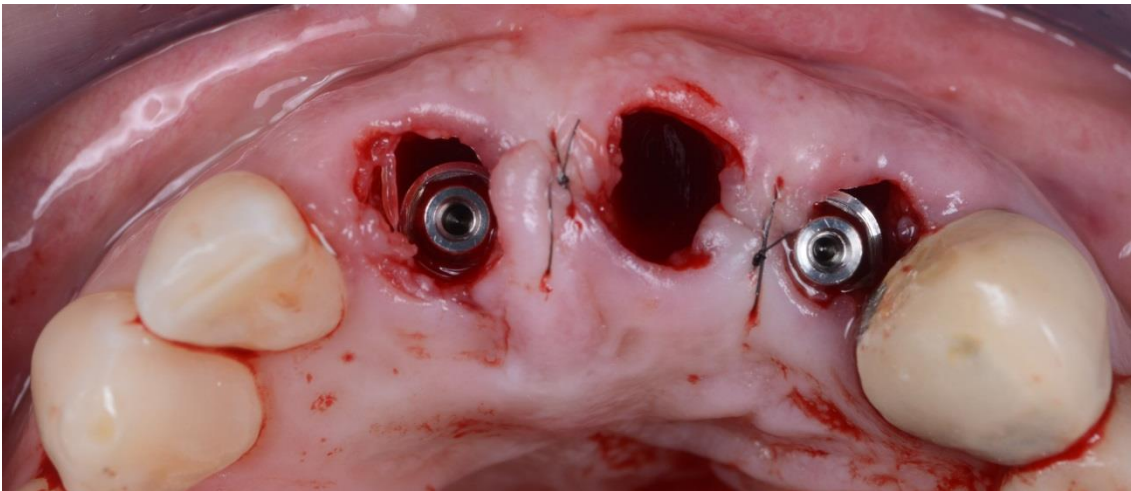
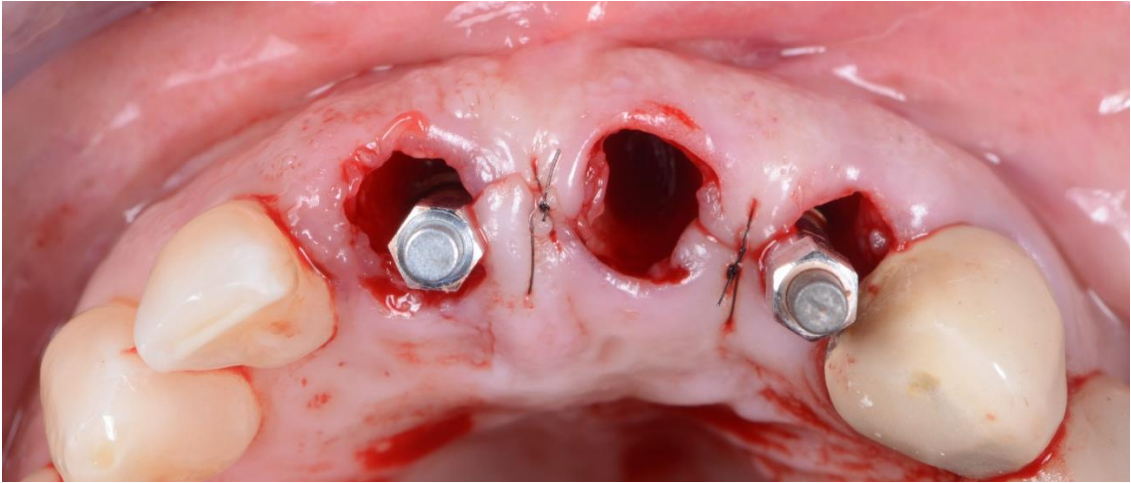


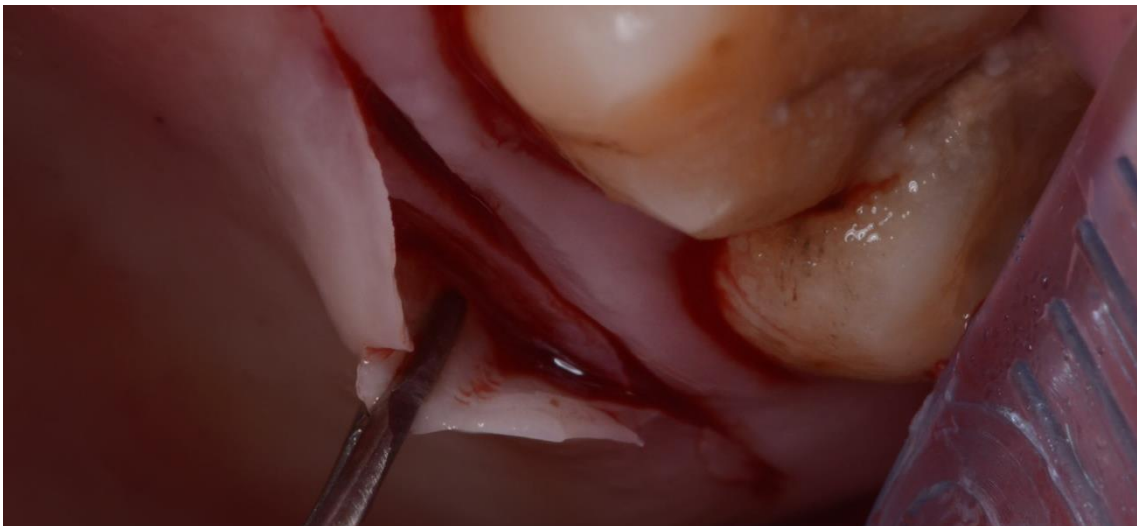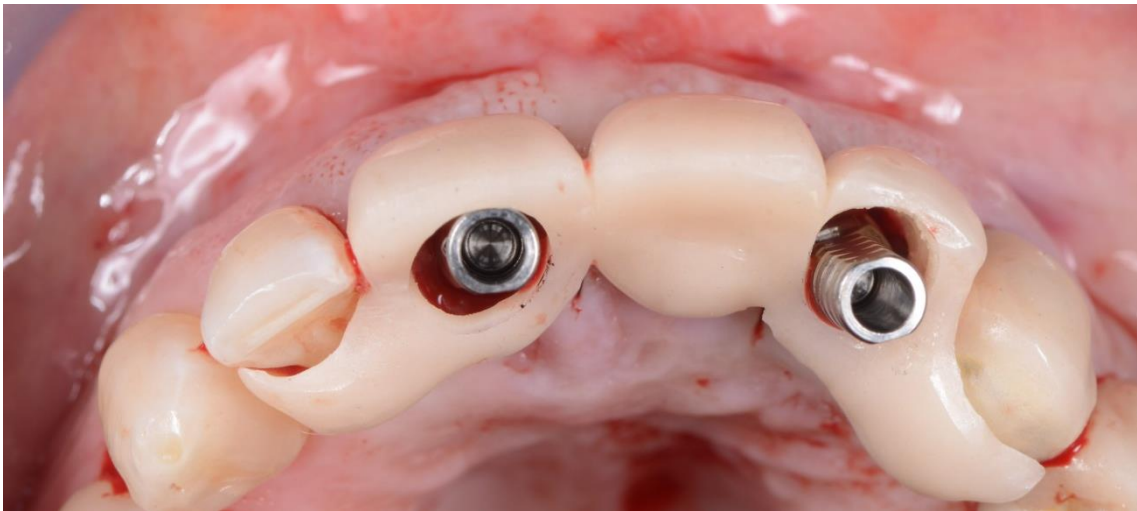
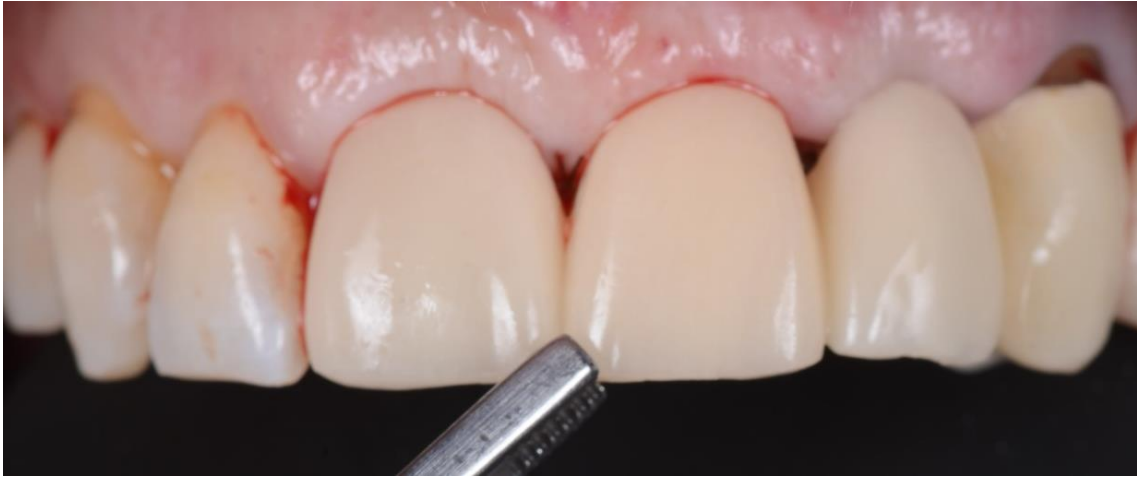CIRUGIA

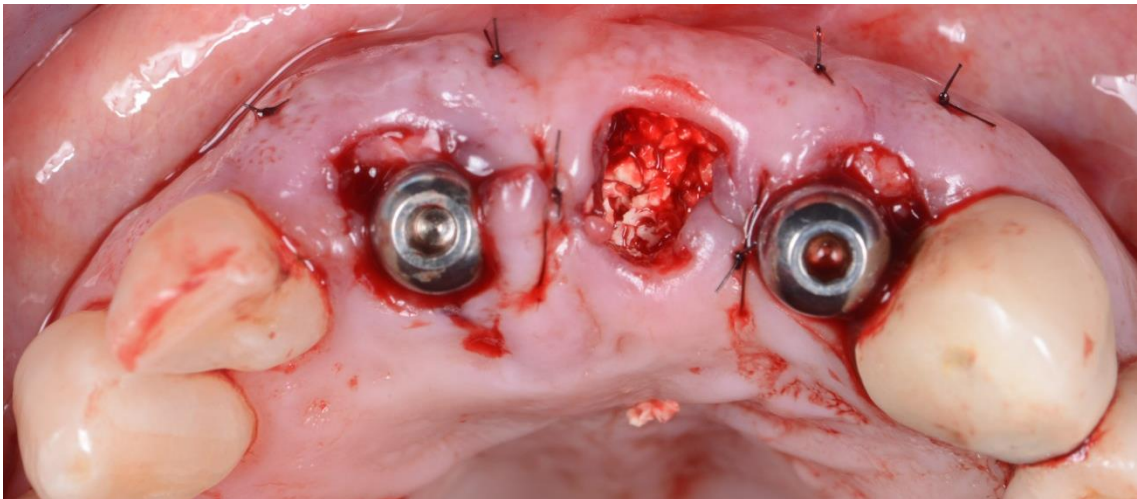
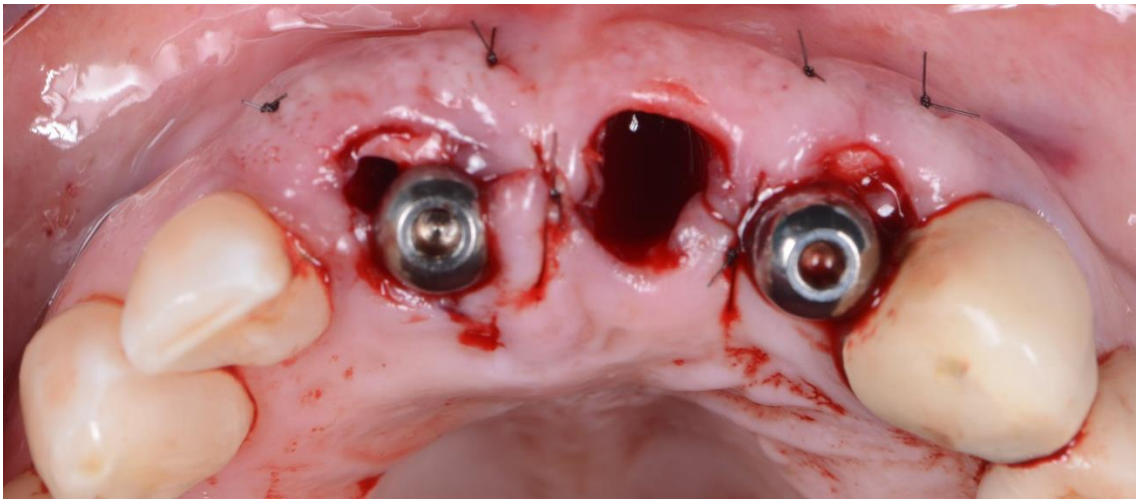
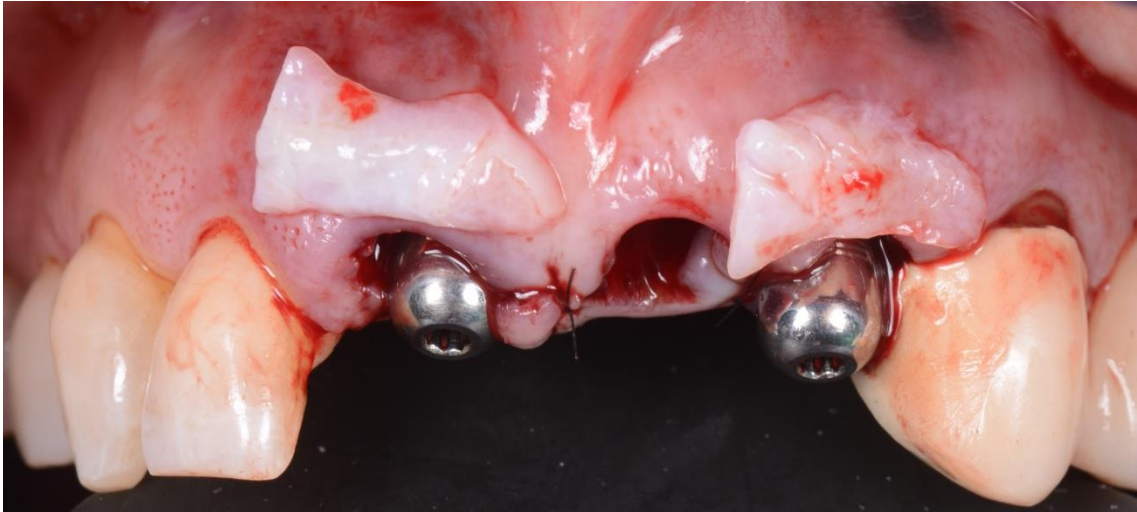

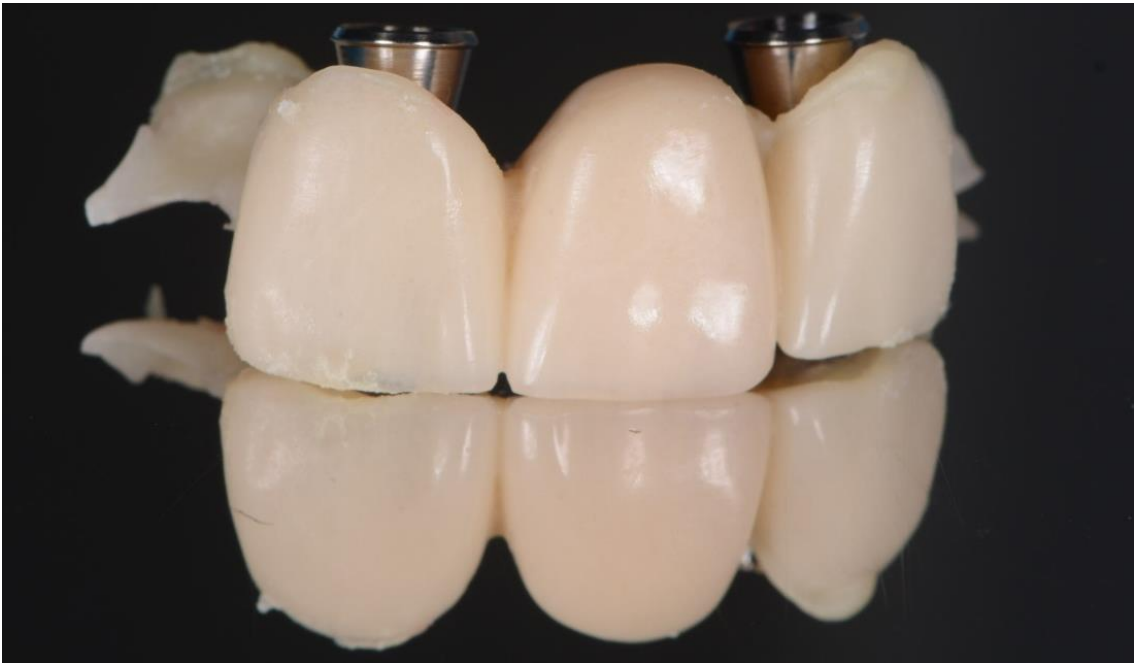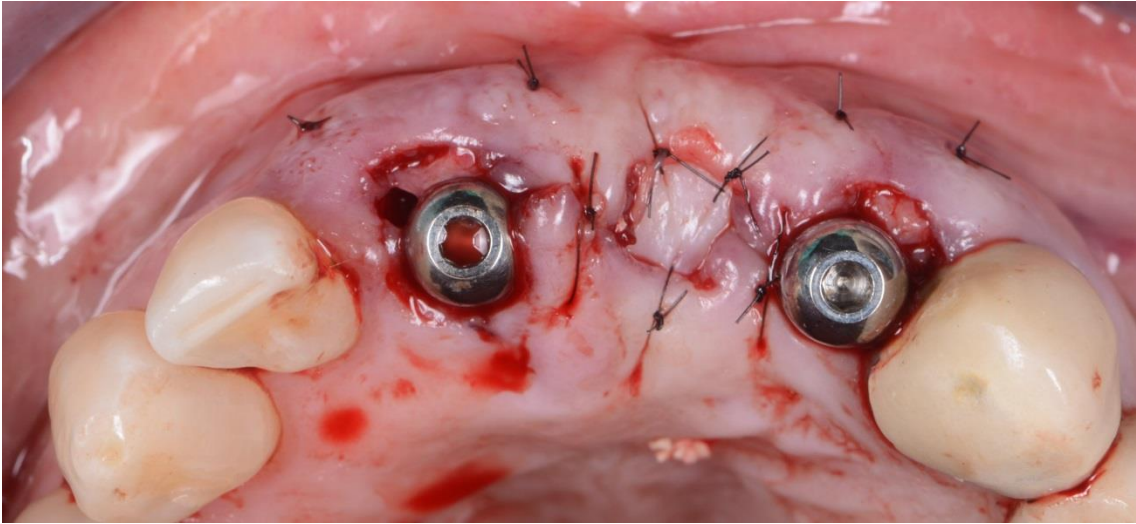




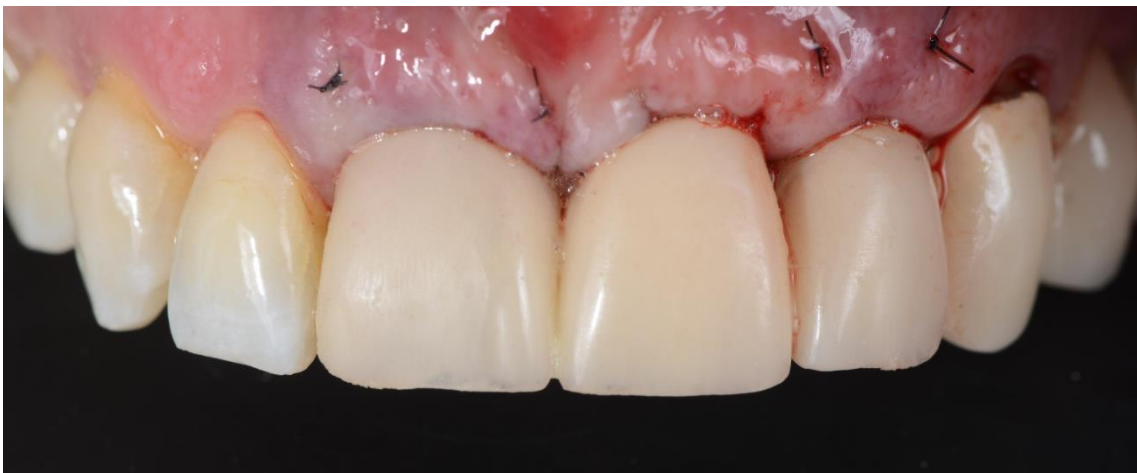
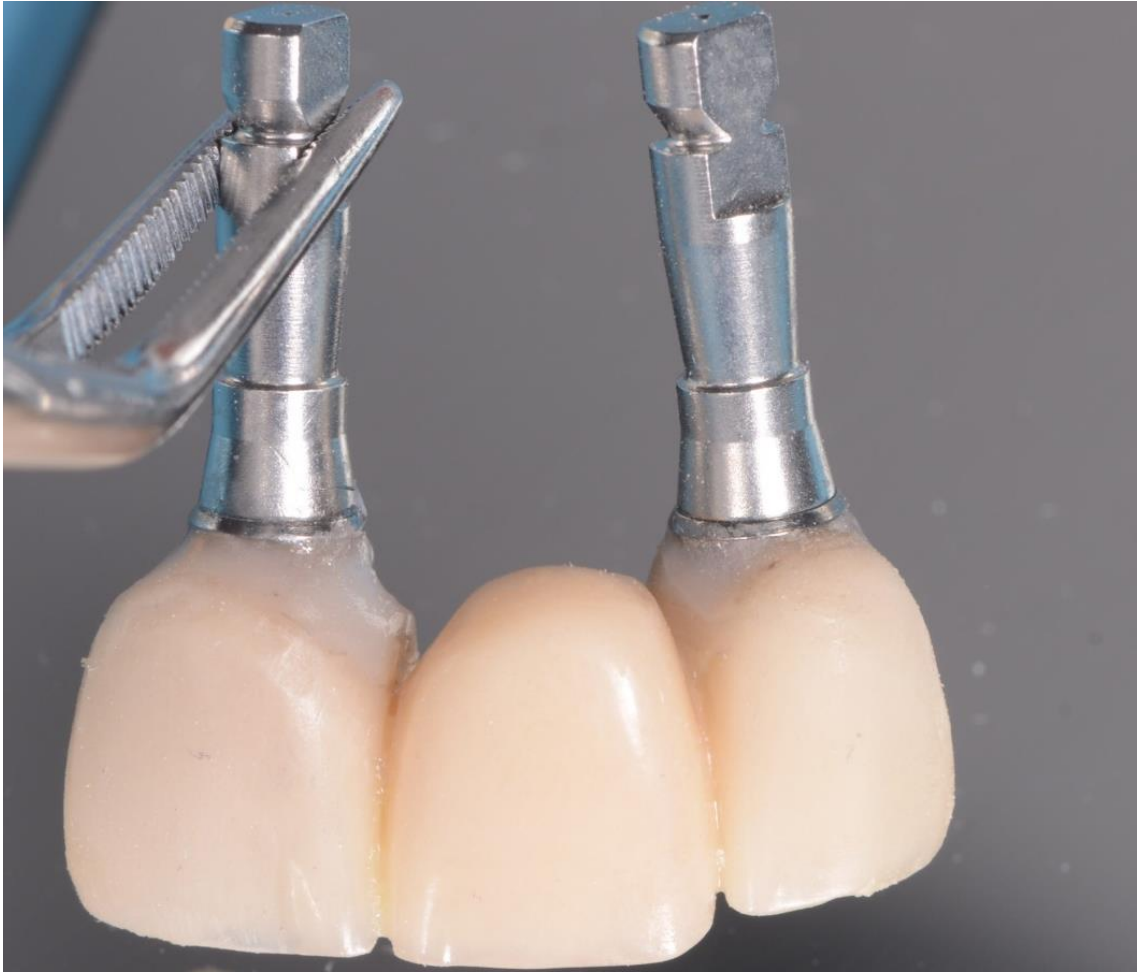
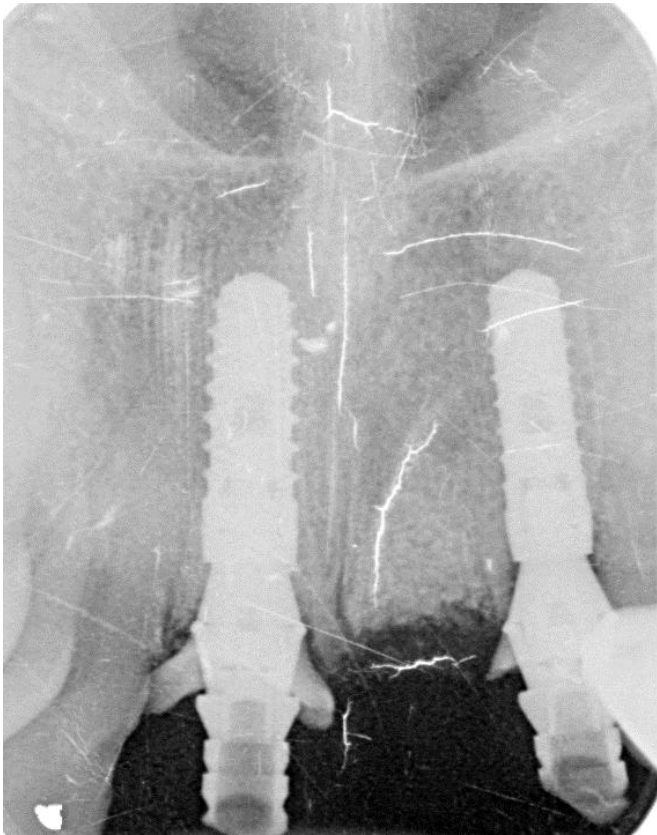








PERIAPICAL POST-QUIRURGICA



DOS SEMANAS DE CICATRIZACIÓN

